



PATIENT

Romeo MacDonald

SPECIES

Feline

BREED

Maine Coon Cat

SEX

Male Neutered

AGE

10 years

WEIGHT

33.4lbs

INTERPRETED BY

Maggie Machen Lamy,
DVM, DACVIM
(Cardiology)

IMAGING PERFORMED BY

Kim Liedberg

HOSPITAL NAME

SVS Imaging WI

REFERRING VET

Dr. Sobon

INVOICE

26883

DATE

10/13/22

PRESENTING CLINICAL SIGNS

History: Acute convulsion as he arrived at RDVM for his exam. Put on O2 right away. Doing better now. No heart murmur noted. Radiographs of chest do not show CHF, but concern is HCM/Thromboembolism vs seizure. Sedated with Midazolam IV .1mg/kg at 8am this morning.

ECHOCARDIOGRAM FINDINGS *image quality limited by patient body condition.

2D, m-mode, color flow and doppler imaging is available. The left ventricular wall thickness is borderline in dimension. There is a mildly hyperechoic endocardium consistent with mild fibrosis. The endocardium also appears mildly remodeled. The papillary muscles are normal in size and hyperechoic. The left atrium is borderline enlarged. The right atrium is normal in size. The right ventricle appears normal. The mitral valve is normal in structure and mobility. No obvious valve regurgitation. Blood flow through both the LVOT and RVOT is normal in velocity. No pleural or pericardial effusion seen. No obvious cardiac tumors.

CARDIAC CHART

FELINE CARDIAC PARAMETERS	BODY WEIGHT (kg)	HR (BPM)	IVSd (cm) (Moise, Pipers)	LVIDd (cm) (Moise, Pipers)	LWVd (cm) (Moise, Pipers)	FS (%)	EF (%)
NORMAL PARAMETER	-----	150-240	0.35-0.55	<2 (mean 1.5)	3.5-0.55	35-67	80-100
PATIENT	15.1	180	0.61	1.5	0.62	40	76
FELINE CARDIAC PARAMETERS	LA/AO (Boon)	LA/AO HEART BASE (Swe) (Abbott)	LA 2D short axis Base view (cm) (Abbott)	LVOT VEL (m/s)	RVOT VEL (m/s)	E max (m/s)	
NORMAL	<1.5	<1.3	<1.2	<1.6	<1.3	<0.9	
PATIENT	1.4	1.2	1.4	1.5	1.0	NM	

**Note: All measurements based upon multi-modal images and methods. An average value is reported.
Adapted from June Boon, Veterinary Echocardiography, 1998
Abbott J & MacLean H JVIM 2006;20: 111-119, Moise et al. Am J Vet Res 47:1476, 1986. Pipers et al. Am J Vet Res 40:882, 1979.*

INTERPRETATION OF THE FINDINGS & FURTHER RECOMMENDATIONS

Overtly normal cardiac structure and function. The LV wall thickness and LA dimension are both borderline for a typical cat; however, this particular patient is extremely large, and this is suspected to be a normal variant. Follow up is advised, particularly given the predisposed breed. Given these findings, no medications are indicated.

These findings would suggest the episode is unlikely to be cardiogenic in origin. Without left atrial enlargement a cardiogenic thrombus is considered extremely unlikely. Further systemic/neurologic evaluation is advised.

Anesthetic risk is considered mild. With remodeling and diastolic stiffening, there is an elevated risk for fluid overload in this patient and judicious IV fluid use is recommended. Heart rate stimulating drugs such as atropine, glycopyrrolate or ketamine should be avoided unless medically necessary. Risk for complication with steroid use typically follows LA dilation, which in this case is low. That being said, any cat can experience unexpected signs of intolerance and monitoring of RR/RE is advised particularly in the initiation phase.

IMAGING PERFORMED BY

svsmobileimaging.com 309-737-3070



Clinical Sonography & Telecytology

EDUCATIONAL TELECONSULTATION SERVICES™

1-800-838-4268 info@sonopath.com SonoPath.com

PATIENT

Romeo MacDonald

Recommend recheck echocardiogram in 1 year to assess for any progressive issues.

SPECIES

Feline

BREED

Maine Coon Cat

SEX

Male Neutered

AGE

10 years

WEIGHT

33.4lbs

INTERPRETED BY

Maggie Machen Lamy,
DVM, DACVIM
(Cardiology)

IMAGING PERFORMED BY

Kim Liedberg

HOSPITAL NAME

SVS Imaging WI

REFERRING VET

Dr. Sobon

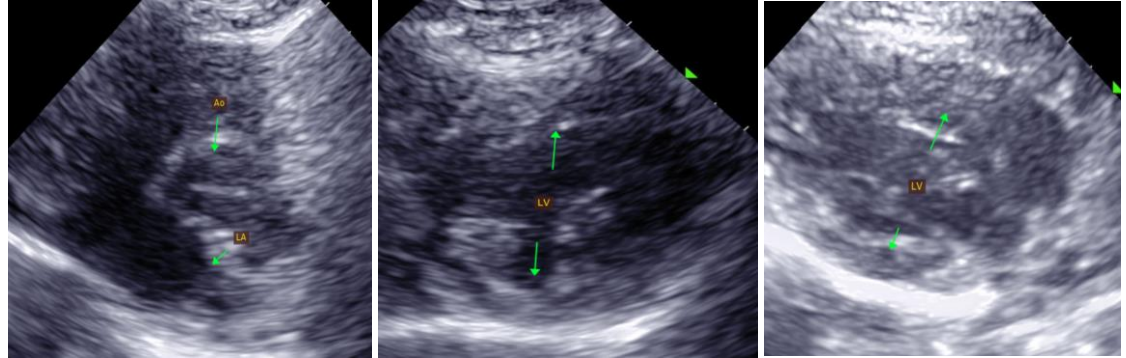
INVOICE

26883

DATE

10/13/22

IMAGES



The information and recommendations provided are based on the images presented by the referring veterinarian. No evaluation can be communicated regarding pathology that was not visible in the image/video clips provided.

Thank you for this referral. If the clinical or image interpretation does not parallel your findings or if I can be of any further assistance, please contact me.

Maggie Machen Lamy, DVM
Diplomate of the American College of Veterinary Internal Medicine (Cardiology)
info@sonopath.com